



PATIENT PRESENTING CLINICAL SIGNS

- Maru Yuan
- chronic ,8/25 right otitis and upper resp signs, snoring
 - r/o polyp
 - first CT imaging with was not saved
- SPECIES**
- we proceeded with deep video otic exam and found polyp
 - polyp removed
- Feline
- we repeated CT to make sure we covered all bases and no other underlying issue present: so this set of images does not have the right ear polyp

BREED

Scottish Fold

COMPUTED TOMOGRAPHIC STUDY OF THE HEAD

Plain study available for review immediately after polyp removal.

SEX COMPUTED TOMOGRAPHIC FINDINGS

FS Hypoattenuating content is present in both tympanic bulla consistent with fluid accumulation Mild thickening of the osseous lining of both tympanic bulla is seen.

AGE

6yr

There is a small nasopharyngeal polyp measuring 6 mm x 4 mm emerging from the right tympanic bulla and extending into the nasopharynx from the right dorsal aspect through the eustachian tube.

Residual tissue or fluid is noted in the medial aspect of the right ear canal following polyp removal. Correlation with video otoscopy recommended.

INTERPRETED BY

Nele Eley (Ondreka),
DVM Dr. med. vet.,
DipECVDI

No destructive bone changes or signs of malignancy are identified.

Cranial bones, sinuses and nasal passages are unremarkable.

COMPUTED TOMOGRAPHIC DIAGNOSIS

HOSPITAL NAME

Tenafly Vet Center

- Chronic bilateral otitis media with fluid accumulation
- Small nasopharyngeal polyp emerging from right bulla
- Post polyp removal residual tissue or fluid in medial aspect of right ear canal. No evidence of malignancy

REFERRING VET

Barnea

INTERPRETATION OF FINDINGS & FURTHER RECOMMENDATIONS

The findings are consistent with chronic middle ear disease with a small right nasopharyngeal polyp. Fluid in the bulla may contribute to ongoing upper airway signs or snoring. No polyps or mass lesions are noted on the left side. There may be residual tissue or fluid in the medial aspect of the right ear canal. Correlation with video otoscopy is recommended to confirm removal completeness and evaluate for residual tissue.

INVOICE

24169

DATE

03/11/2026



PATIENT

Maru Yuan

SPECIES

Feline

BREED

Scottish Fold

SEX

FS

AGE

6yr

INTERPRETED BY

Nele Eley (Ondreka),
DVM Dr. med. vet.,
DipECVDI

HOSPITAL NAME

Tenafly Vet Center

REFERRING VET

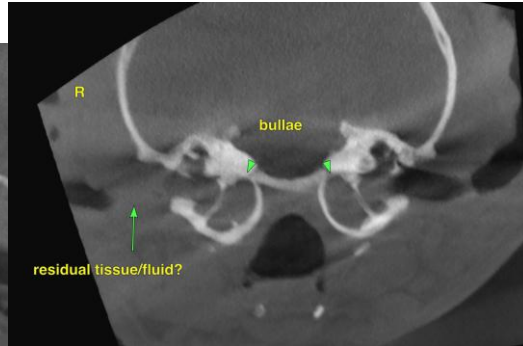
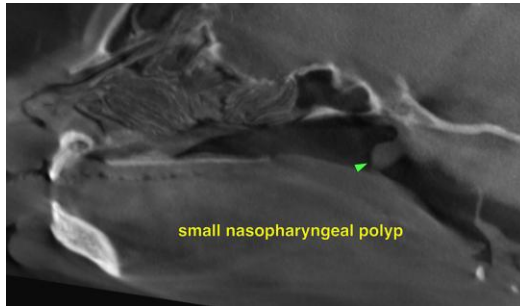
Barnea

INVOICE

24169

DATE

03/11/2026



The information and recommendations provided are based on the images presented by the referring veterinarian. No evaluation can be communicated regarding pathology that was not visible in the image/video clips provided.

Thank you for this referral. If the clinical or image interpretation does not parallel your findings or if I can be of any further assistance please contact me.

Nele Eley (Ondreka), DVM, Dr. med. vet., DipECVDI
European Specialist in Veterinary Diagnostic Imaging, Cert. Radiology,
Senior lecturer University of Giessen/Germany, Veterinary Faculty, Department of Radiology.
info@sonopath.com